



# Abdominoplasty and Abdominal Wall Rehabilitation: A Comprehensive Approach

Oscar M. Ramirez, M.D.

Baltimore, Md.

Standard abdominoplasty techniques involve a low horizontal or W skin excision, muscle plication, and umbilical transposition. Newer techniques include suction-assisted lipectomy, the use of high lateral tension with fascial suspension, and external oblique muscle advancement. The author has modified these traditional procedures and added new techniques to improve the aesthetic and functional results of the abdominoplasty procedure. This modification provides a comprehensive approach to abdominal wall aesthetic improvement and rehabilitation. The comprehensive approach described includes four components: the "U-M dermolipectomy," "V umbilicoplasty," the rectus abdominis "myofascial release," and suction-assisted lipectomy. The patient is marked while standing for areas of suction lipectomy and undermining. The lower incision is designed as an open U with the lateral limbs placed inside the bikini line. The upper incision is a lazy M with the higher peaks located at the level of the flanks. Subcutaneous hydration is achieved to perform suction along the flanks, waistline, and iliac areas. Gentle suction of the flaps is also performed. The umbilicus is cored out in a heart shape. The flaps within the U-M marks are excised, and the undermining is performed to the xiphoid and costal margins. The rectus diastasis is marked, and the anterior rectus fascia is incised at the junction of the medial third with the central third of the width of the rectus sheath. Horizontal figure-eight plication sutures by using the lateral fascial edge enable easier infolding of the central tissue. The new recipient of the umbilicus is made by an incision in a V shape on the abdominal flap. The umbilicus is telescoped, and the triangular flap of the abdomen is sutured to the triangular defect of the umbilicus. Skin flap fixation to the umbilicus relieves tension in the lower portion of the flap. The upper skin flap, which is cut in an M manner, provides lateral tension and matches the length of the lower flap. A standard fascial suspension is used and closure is performed in layers. The techniques described here are intertwined procedures. Each facilitates the accomplishment of the other procedure, and they complement each other. They all attain the 12 objectives of the abdominoplasty described. These combined techniques have been used in 104 patients in a period of 11 years. Complications were minimal and easily manageable, except for one patient who required excision of a pseudobursa and retightening of the lower quadrants of the abdominal wall musculature to correct extreme

lordosis. A comprehensive approach for the treatment of complex abdominal wall aesthetic and functional defects is presented. These require thoughtful integration of the four components mentioned. This approach has allowed predictable, reproducible, and aesthetically pleasing results. (*Plast. Reconstr. Surg.* 105: 425, 2000.)

Traditional abdominoplasty techniques for severe deformities include the following procedures: (1) "dermolipectomy" for removal of excess fat and skin, (2) "plication" of the anterior rectus sheath for muscle diastasis, and (3) transposition of the umbilicus to a new location in the abdominal wall skin. Newer techniques developed in the past few years include (1) suction-assisted lipectomy, (2) high lateral tension closure with fascial suspension, and (3) external oblique fascial advancement to create a smaller waistline.

Some of these techniques may have drawbacks, and the newer maneuvers, particularly the external oblique muscle advancement, can be technically challenging. Therefore, the author has modified these traditional procedures and added new techniques to improve the aesthetics and functional results of the abdominoplasty procedure. I postulate that the combination of these techniques provides a comprehensive approach to abdominal wall rehabilitation with superior aesthetic results.

### OBJECTIVES OF ABDOMINOPLASTY

Every abdominoplasty should have the following objectives, and every described technique should be measured against these objectives: (1) place the incisions within the bikini line; (2) reduce or eliminate striae; (3) flatten and tighten the abdomen; (4) decrease the size

of the waistline; (5) decrease the thickness of the subcutaneous fat throughout the abdomen, flanks, and iliac areas; (6) rejuvenate the pubis from a triangular senescent to an oval youthful form; (7) lift the lax anterolateral thigh skin near the groin crease and iliac areas; (8) create a well-defined xiphoumbilical depression; (9) give an illusion of an athletic abdomen, (10) change body posture; (11) correct any hernia; (12) relieve back pain if this is related to muscle laxity of the abdomen.

The technique described herein attains these objectives. In many patients with severe aesthetic and functional problems, it is a truly rehabilitative operation. In all, there are four surgical components.

#### *First Component: The "U-M" Dermolipectomy*

The U-M abdominoplasty was designed to place the incisions inside the aesthetic units of the abdomen.<sup>1</sup> Conceptionally, this incision is very similar to the "bicycle handlebar" described by Baroudi and Ferreira.<sup>2</sup> The U-M incision includes an open U and a lazy M (Figs. 1 and 2). This particular geometrical design accomplishes several goals: (1) The length of the lower incision matches the length of the upper incision. This technique makes less likely an interminable chase of the "dog-ears" at the end of the incisions. (2) The final closure finishes within the abdominal wall aesthetic units and follows a parallel line to a "french-cut" bikini. (3) The concept of high lateral tension is incorporated in the design, which lifts the lax anterolateral thigh.<sup>3</sup> (4) Because the pubic incision is very low, it diminishes the size of the pubis and also lifts the

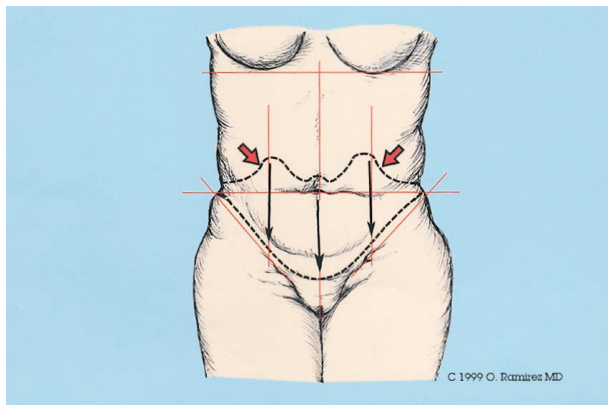


FIG. 1. The front view of the outline of the U-M dermolipectomy component. The lower incision is an open U and the upper incision is a lazy M. The vertical and horizontal lines and the groin lines help marking of the flaps in a symmetrical manner.

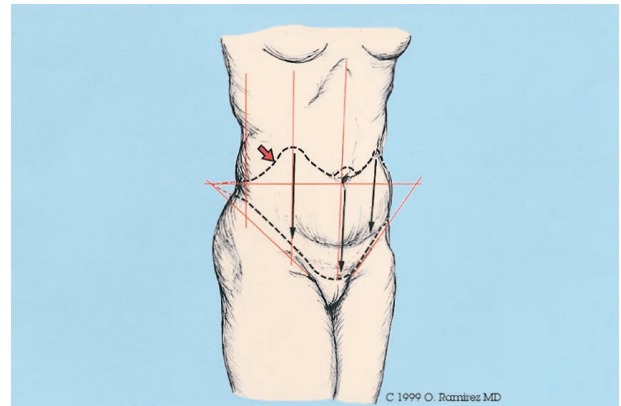


FIG. 2. Three-quarters view of the U-M dermolipectomy component. Observe that the U incision starts very low in the pubis and travels parallel to the groin line toward the waistline.

pubic area, changing the shape from a senescent, triangular form to an oval, youthful one.

#### *Second Component: "V" Umbilicoplasty*

One method of coring out the umbilicus for transposition during an abdominoplasty is through a circular incision. The recipient incision is also a circular defect. This may produce a constricting scar contracture that narrows the umbilical opening. To avoid this problem, we have designed the umbilical incision by excising a triangular flap on the upper or lower meridian of the umbilicus (Fig. 3, left). The location of this will depend on patient's desire to have a "frowning" or "smiling" navel. The V incision gives a "smiling" appearance, whereas

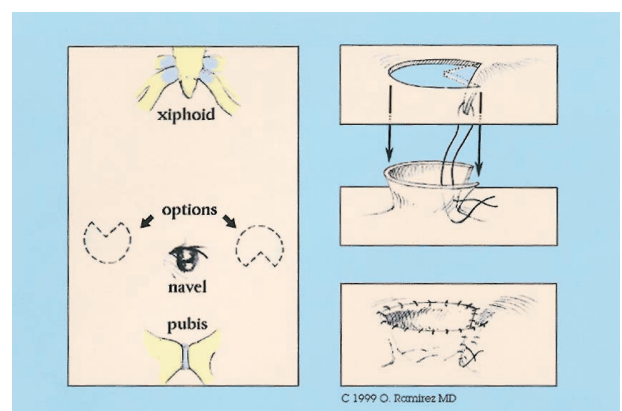


FIG. 3. (Left) An incision in the navel is made in a heart shape with a triangular component left in the abdominal flap in a superior or inferior orientation. (Right) A corresponding triangular incision is made on the recipient site of the abdominal wall for inseting of the umbilicus. The triangular flap is inset into the triangular defect of the navel, and the rest is closed in two layers circumferentially. The umbilicus is telescoped with the dermis anchored to the border of the rectus fascia.

the inverted V gives a “frowning” navel. The V incision seems to be preferred by patients. I also favor this incision because it helps to anchor the upper abdominal flap to the navel and reduces tension on the lower flap at the pubic line closure (the portion of the flap with more risk of vascular compromise). The recipient defect of the navel is created by a reciprocal, triangular incision of the abdominal flap. The tension in the abdominal flap will create the heart-shaped defect, and the triangular flap is inset in the triangular defect of the navel (Fig. 3, right). The most important feature of the V umbilicoplasty is that it avoids a concentric scar contracture. This technique is a modification of a previous work presented by Juri et al.<sup>4</sup>

*Third Component: The Rectus Abdominis “Myofascial Release” and Repair*

The traditional method of correcting diastasis recti is by plicating one intact anterior rectus sheath against the opposite member (Fig. 4, left). This method usually creates significant tension as the anterior rectus fascia is advanced over the encased rectus muscles toward the midline. This technique may produce significant postoperative pain. Furthermore, it will be ineffective in defining the waistline. To avoid these problems, we have applied to our abdominoplasties a technique I have called “rectus abdominis myofascial release” (Fig. 4, right). This technique is an offspring of the experience gained using the “component separation” method for closure of abdominal wall defects.<sup>5</sup> The anatomic and physical principle is that a gradual release and undermining of

the components of the abdominal wall diminishes the index of tension during abdominal wall closure.<sup>6</sup> Therefore, the first step is to incise the anterior rectus sheath at the junction of the inner one-third with the middle third of the rectus muscle width. In cases of significant abdominal laxity, this incision is made at about half of the rectus width. These incisions meet at the level of the xiphoid process superiorly and the pubis inferiorly (Fig. 5). The rectus myofascial release allows the centrifugal forces of the rectus muscles to push the muscles toward the midline, facilitating closure with decreased tension. It also allows better pull of the external oblique muscle, which in turn will be more effective in redefining and decreasing the waistline measurements (Fig. 6). The average width of advancement at the level of the navel is 10.5 cm. It varies from 6 to 18 cm.

*Fourth Component: Suction-Assisted Lipectomy*

Most patients with skin excess also have a thick panniculus on the abdomen and neighboring areas. This requires contouring by means of suction lipectomy at the time of the abdominoplasty. Although, ideally, total contouring with suction should be done as a preliminary stage to abdominoplasty, in reality, this is almost impossible. This staged approach is reserved only for the high-risk (class III) patient.<sup>7</sup> Patients of class I and II can have the combined procedure, but the suction lipectomy should be attempted with caution and the patient should be informed about the potential increased risk if liposuction beyond minor contouring is planned.

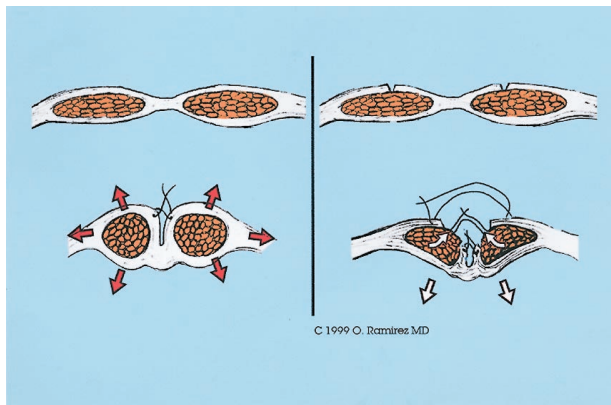


FIG. 4. (Left) The standard muscle plication with the intact rectus sheath creates significant centrifugal forces against the rectus repair. (Right) The myofascial release of the rectus muscle previously encased in the rectus sheath facilitates tremendously the midline closure with decreased tension.

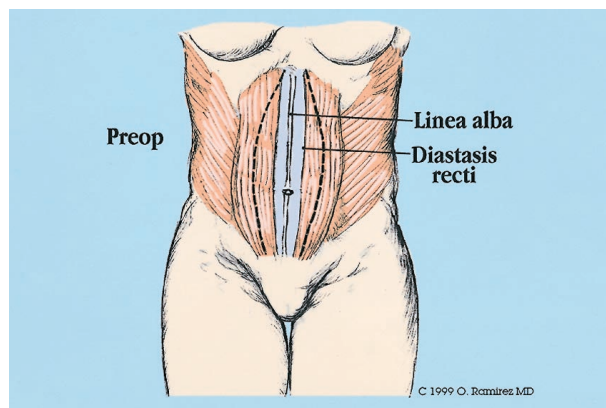


FIG. 5. The myofascial release is done about the junction between the medial third and the central third of the width of the rectus sheath. Incisions meet at the xiphoid and suprapubic areas.

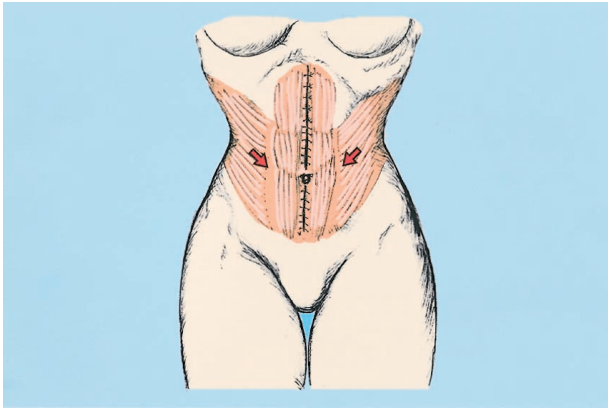


FIG. 6. Repair after myofascial release with advancement of the lateral external rectus sheath provides significant pulling over the external oblique muscles and indirectly into the internal oblique-transverse abdominis muscles. This method produces a nice and effective abdominal cinch.

When suction-assisted lipectomy is performed at the time of the abdominoplasty, I usually follow the recommendations described by Matarasso<sup>7</sup> with only one exception: the new xiphoumbilical depression is suctioned more liberally. As advised by him, I also would not recommend suction in the central portion of the flap below the new umbilical position. Suction is done with small cannulas, i.e., 2 to 3 mm, following the axial orientation of the vessels outside and inside the "vascular arc" except in the new xiphoumbilical midline, where by its nature, the suction should be done in a vertical direction.

#### SURGICAL TECHNIQUE

##### *Preoperative Management*

Plication techniques, myofascial advancements, or both, will compress the contents of the abdominal cavity. This will produce a significant counterforce toward the redefined abdominal wall, producing pain, potential dehiscence, and ileus paralyticus. The latter will increase further the internal pressure, creating an increasingly deteriorating vicious cycle. If the patient vomits, it will increase even more the tension against the myofascial suture line closure. The increase in abdominal pressure will also compress the posterior abdominal structures from which the inferior vena cava is the most compressible. This will produce a stagnation of the venous return with the subsequent potential development of massive deep venous thrombosis. To avoid this chain of events, it is essential to prevent bowel distention by the following maneuvers: a good bowel

preparation that includes a clear liquid diet for 2 to 3 days before surgery, laxatives, enemas, and antibiotics to decrease the growth of bacteria flora responsible for intestinal gas and stool production. In addition, I include in my regimen Reglan (chlorpropamide) 10 mg orally every 6 hours to decrease production of gastrointestinal juice and to stimulate peristalsis of bowels in the early postoperative period. This regimen has made postoperative recovery easier and less painful. Most importantly, we have seen only one case of minor deep venous thrombosis (at the calf) and no cases of postoperative ileus paralyticus or abdominal distention.

##### *Preoperative Markings*

Markings are made in the standing position. Reference marks are outlined initially. These include groin lines with direct extension into the upper iliac areas, central midline of the abdomen, parallel lines to the central midline that crosses the flanks, a vertical line on the silhouette of the patient that crosses the waistline and lateral hip areas. Another line perpendicular to the midline is made across the abdomen usually at the level of the navel. These reference lines are useful for markings of the planned flap excision as symmetrical as possible (Figs. 1 and 2).

The open U is marked first. For this, the pubic skin is lifted and a horizontal line is marked, leaving a reasonable pubic size. This mark is approximately 5 to 7 cm from the anterior vulvar commissure. The line extends just medial to the groin areas. From here, the direction of the line is quickly diverted toward the waistline area. During this process, one surgeon's hand elevates the thigh skin in a vertical direction. The procedure is repeated on the contralateral side.

The lazy M is marked next. This design has a sequence of hills and valleys with the central portion just above the umbilicus and the highest point at the level of the linea semicircularis. A gentle slope is constructed about the flank areas, and this line gradually tapers to meet the uppermost extension of the U component. The M configuration can change slightly to adapt to the areas of more skin laxity or tension.

##### *The Operation*

Surgery is performed under general anesthesia. Intermittent compression devices are ap-

plied to the lower extremities. Dissection is performed under "subcutaneous hydration." We prefer this concept rather than the "tumescent" concept because we do not want to produce the "orange peel" appearance on the abdominal flaps. We believe that the "tumescent" technique hinders the blood supply of the flaps, particularly if the flaps have to be elevated.<sup>8</sup> Suction-assisted lipectomy of the iliac areas and waistline is routinely performed with 4- to 5-mm cannulas. I avoid suctioning the pubis; its shortening and lifting will usually decrease its bulk. The central thickness of the subcutaneous layer of the flap to be advanced inferiorly is suctioned with 2- to 3-mm cannulas. If suction is performed, this procedure should follow the orientation of the vascular supply to the abdominal flaps, namely an oblique direction from inferior to superior and from medial to lateral. Extreme caution is advised to avoid compromising the blood supply of the abdominal flap. The portion of flap above the position of the new umbilicus is suctioned up to the subdermal layer to create the xiphumbilical depression. This is done through the recipient defect made for the navel and by using small cannulas. Etching in the midline below the umbilicus is never performed, to avoid vascular compromise of the infraumbilical flap. From the aesthetic point of view, this etching is not needed.

Dermolipectomy is done by incising, initially, the U component. Flap elevation is done with the electrocautery; however, the large perforators are better handled by suture ligation or application of hemoclips. This method will ensure complete hemostasis and avoid potential bleeding postoperatively during coughing. The large vessels underneath the useful portion of the flap are also suture ligated rather than electrocoagulated to avoid spread of heat damage on its corresponding vascular tree. When dissection approaches the navel, this is cored out after the incision in the navel is done, as will be explained in the umbilicoplasty section. Dissection extends up to the costal margins and the xiphoid areas. A trial of advancement of the flap with the operative table bent to 45 degrees is made. The previously marked upper incision (M component) is matched against the lower incision. If any discrepancy exists, appropriate adjustments are made before committing yourself to the final flap trim.

If a smaller abdominoplasty is required and

the pubic-umbilicus distance is high, you could perform an "umbilical float" procedure by using the U-M abdominoplasty pattern. However, with this technique, the navel could be repositioned 2 or 3 cm only. The use of this variation is limited to a very small group of patients.

The abdominal muscle repair is done after the abdominal skin flap is elevated. Although variations in the fascial closure are made to address specific patients' problems, in the majority of patients, the technique used is as follows: The rectus diastasis is marked and an elliptical shape from xiphoid to pubis on the anterior rectus sheath is marked with the widest portion around the navel. This ellipse varies from 6 to 18 cm with an average of 10.5 cm (5.25 cm to each side of the midline). About 1-cm incisions every 3 to 4 cm in an interrupted manner are made along the markings on the anterior rectus sheath by using the cold knife. The hemostat is introduced in each incision, the fascia elevated, and the initial incisions is connected with electrocautery (Fig. 7, *above*). The area of the tendinous inscriptions is avoided. Occasionally, you may encounter a musculocutaneous perforator, which is suture ligated. The midline repair is done with 0 to no. 2 Tevdek (Deknatal DSP, Fall River, Mass.). Suture size depends on the strength of the tissues. The sutures are applied in a horizontal figure-eight with inverted knots. Two key sutures are applied, one just above and another one just below the navel (about 3 to 4 cm equal distance). The navel can be seen to drop immediately a few cm below the level of the rectus repair line. To avoid potential difficulty in retrieving the navel, a 3-0 nylon suture tie is applied to it. The rest of the myofascial repair is done from xiphoid to pubis (Fig. 7, *below*). If the abdominal laxity is significant and/or the waistline measurements must be decreased significantly, then the medial border of the rectus muscle is repaired in the midline and independently the lateral rectus fascia, which is dissected laterally to the linea semicircularis, is advanced over and repaired in the midline. This approach will provide a more effective traction on the external oblique muscle and decrease the size of the waistline. To aid in muscle relaxation and avoid pain in the first 24 hours, the abdominal muscles are infiltrated with 0.25% bupivacaine mixed with 1:100,000 epinephrine solution. About 80 to 100 cc of this solution is injected just underneath the external fascial layers of the rectus and external oblique muscles by using long blunt needles

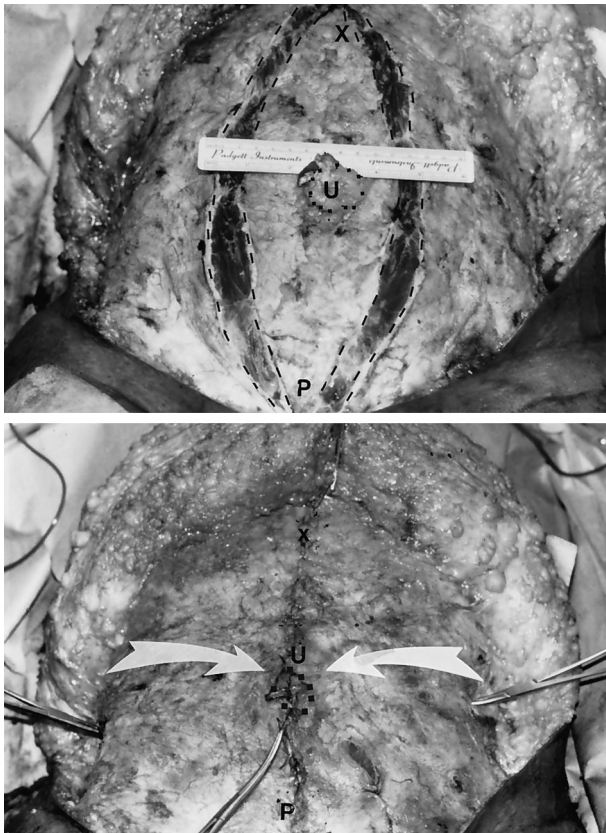

FIG. 7. (*Above*) Intraoperative view of the myofascial release with incisions meeting around the xiphoid and supra-pubic areas. The widest area of the incision is around the navel. *U*, umbilicus; *P*, pubis; *X*, xiphoid. (*Below*) Completion of the lateral rectus sheath repair with decrease of the width of the abdominal girth. Arrows pointing to the umbilicus (*U*) and the forces around the waistline. *X*, xiphoid; *P*, pubis.

used for epidural anesthesia (Tuey needles). The trajectory of the needle must be visualized throughout the entire length by the translucency of the fascia. This way, you will avoid inadvertent injection deep in the abdomen or in the muscle itself. The higher concentration of epinephrine in relation to the bupivacaine is to make its absorption very slow.

The umbilicoplasty has several steps (Fig. 3): first, the navel is cored out after a heart-shaped incision on its periphery is made. This procedure requires the excision of a triangular flap of navel skin in a superior or inferior meridian. The usually long umbilical stalk is telescoped with sutures applied from subdermis to fascia layer of the rectus. During the trial of flap closure, the umbilical demarcator is used to locate the navel's new position in the abdominal wall skin. After this is done, a triangular incision is done on the abdominal skin. Upon traction of the flap, the defect becomes a heart-

shaped one. The skin recipient around the new navel position is defatted to simulate a similar concavity around the navel seen in the ideal abdomen. The navel is inset in its new position in the abdominal wall in two layers by using nonabsorbable suture material.

Trimming of the upper abdominal flap is done with incision of the skin at a 90-degree angle in relation to the surface and the subcutaneous/Scarpa's fascia layer at a 45-degree angle. This approach is because these last structures are usually retracted superiorly with the initial incision. When closure of this layer is made, it will fit exactly at the suture line and it will not be redundant. Abdominal flap closure is done in two to three layers. The initial layer of sutures is applied at the midline, to centralize the midline. Another key suture is applied midway between the midline and the end of the suture line closure with the upper flap pushed toward the midline. This way, the upper flaps near the midline are closed with minimal or no tension. The final closure is performed from lateral to medial, always with the upper flap being constantly shifted manually toward the midline, because the natural tendency of this flap is to rotate laterally. Two closed-system suction drains are left under the flaps with the ends toward the flanks and in a crisscrossed manner. Topifoam (LySonic, Inc., Carpinteria, Calif.) dressing and a well-contoured abdominal binder are applied.

#### *Postoperative Management*

After surgery, intravenous fluids and intravenous antibiotics are given for 24 hours. Ambulation is started the next day. A clear liquid diet is given for 3 or more days. Supportive stockings and intermittent compression devices are used until full ambulation is obtained. Chlorpropamide 10 mg every 6 hours orally and stool softeners are given until regular bowel movement is obtained. Drains are advanced at the third or fourth postoperative day. They are removed when fluid collection is <20 cc per 24 hours per drain or at 5 days postoperatively, whichever comes first. An abdominal binder is used for several weeks postoperatively. Driving is allowed at 3 to 4 weeks postoperatively. Brisk walking is allowed at 6 to 8 weeks, jogging at 10 to 12 weeks, and exercise without restriction after 14 to 16 weeks.

## CLINICAL EXPERIENCE

The comprehensive approach described in this study has been used in our practice since 1988. One hundred four patients have received this combined procedure. Patients in whom alloplastic materials were used for abdominal wall repair are not included in this report. Patient satisfaction has been extremely high, and the complication rate is small. We have had three patients with small areas of skin necrosis ( $5 \times 4$  cm,  $3 \times 4$  cm, and  $3 \times 3$  cm, respectively) in the lower central abdominal flap. Two patients required secondary revision, one 3 weeks postoperatively and another one several months later. These revisions did not compromise the final aesthetic or functional result. Five patients developed seroma that required serial aspiration of fluid. One patient required excision of a pseudobursa for chronic fluid collection; this same patient required further tightening of lower quadrants on the lower abdominal wall musculature, mostly to correct her body posture (extreme lordosis). One patient developed a drain tract infection treated successfully with drainage and antibiotics. No secondary hernias were seen. Twenty-six patients having moderate or severe back pain were completely relieved of their pain. All patients gained improvements in their posture and how their clothing fit. Many patients began wearing bikini bathing suits that they were unwilling to wear preoperatively. In 20 consecutive patients, we measured the waist circumference preoperatively and at 6 months postoperatively. There was an average 10.5-cm reduction in waist size, ranging from 6 to 18 cm (Figs. 8 through 10).

## DISCUSSION

Most patients with a small lower abdominal "pouch" will benefit from a smaller procedure such as a suction lipectomy,<sup>9</sup> mini-abdominoplasty,<sup>10</sup> or an endoscopic abdominoplasty.<sup>11</sup> However, patients with a large abdominal "apron," severe laxity, or wide diastasis of the rectus muscles represent a completely different clinical problem that requires a more radical approach. This group of patients usually have several aesthetic and functional problems, each of which requires attention. The procedures described in this study were designed to correct most of those problems: to remove the excess abdominal skin, to tighten the lax anterolateral thigh skin, to rejuvenate the ptotic

pubis, to improve the waistline, and to tighten the lax abdominal wall musculature. This correction in turn helped to improve the posture of the torso and in many cases improved the back pain in patients affected by this condition. Because the location of the final scars was an esthetically pleasing, many patients were able to wear two-piece bathing suits, which they were unwilling to do before surgery (Fig. 9).

The method of umbilicoplasty gave a natural appearance without a constricting scar or narrowing of the opening. The midline abdominal etching produced a xiphumbilical depression giving the appearance of an athletic abdominal wall with an illusion of a "prominent" rectus muscle.

The four procedures described here, i.e., U-M abdominoplasty, suction lipectomy, rectus myofascial release, and umbilicoplasty, are intertwined procedures. Although each of the described procedures could be individually integrated into each surgeon's preferred abdominoplasty approach, they work best if done all four together. Each facilitates the accomplishment of the other procedure, and they complement each other. The U-M abdominoplasty component allows easy removal of tissue (skin and fat) around the waistline, allowing the creation of a smaller waistline. Suction lipectomy helps to better contour the abdomen and gives better definition to the distal ends of the line of closure. The myofascial release also allows better definition of the waistline because of the pull of the internal oblique and external oblique muscles toward the midline. The myofascial release and repair also decreases the entire surface of the abdominal wall, which in turn permits removal of more skin/fat from the abdominal wall. The myofascial release also allows shortening and telescoping of the long umbilical stalk. The V-umbilicoplasty, in addition to making the navel scar less conspicuous, allows anchoring of the upper abdominal flap to decrease tension on the pubic line closure. This method allows the safe removal of enough skin to provide the optimal aesthetic result.

The location of the final incision medial and superior to the anterosuperior iliac spine allows the abdominal flap to rest in better contact with the musculofascial layer of the abdomen. Incisions located at or below the anterosuperior iliac spine produce a tenting effect on the flap, and this does not lie flat on the abdominal wall musculature, creating a potential space for the formation of seroma. This

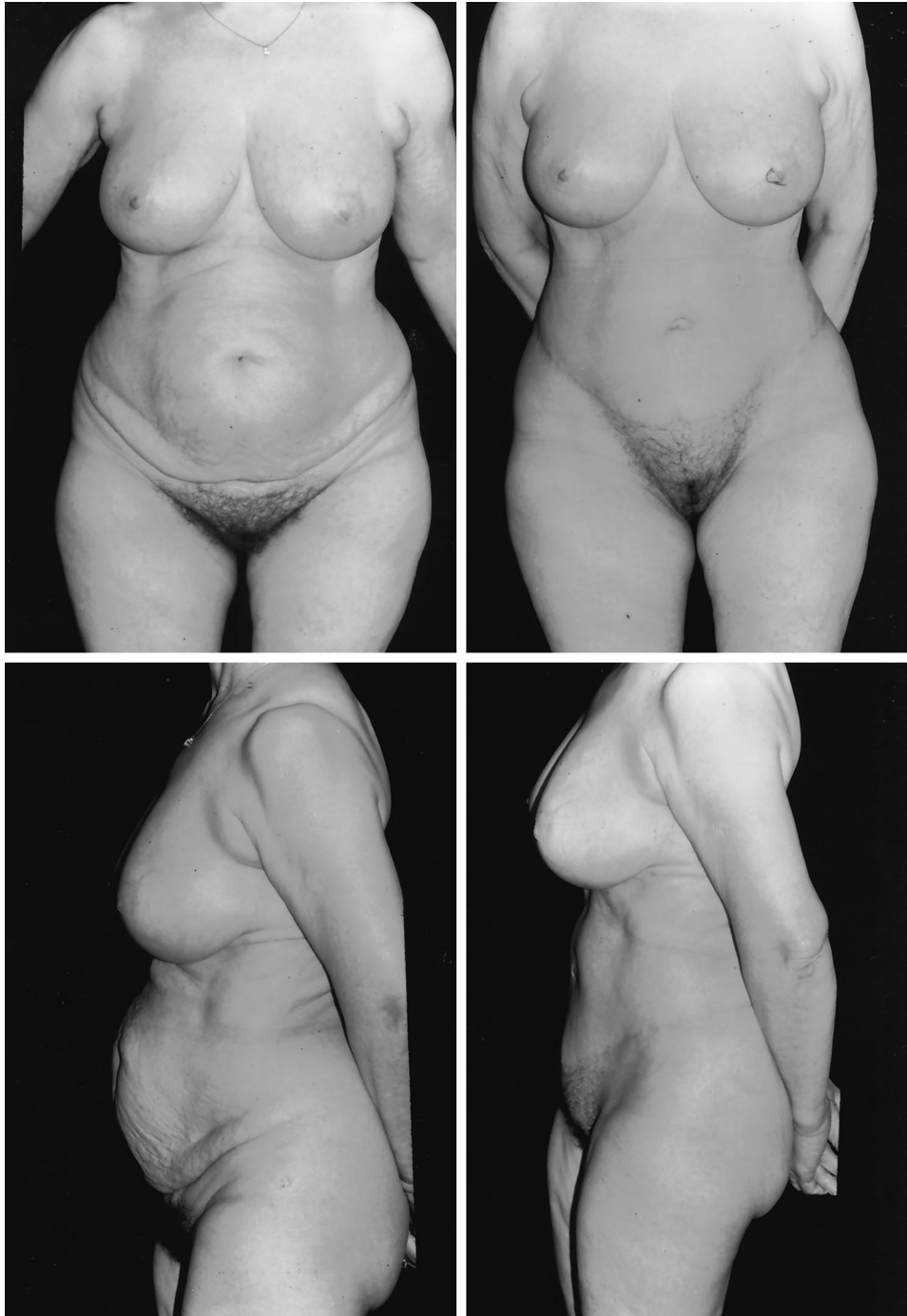


FIG. 8. (*Above, left*) Preoperative anteroposterior view of a 54-year-old woman with folding of skin in the lower abdomen, significant weakness of the abdominal wall, and poor body posture. Observe the triangular senescent pubic area. (*Above, right*) Postoperative anteroposterior view. Observe the rejuvenation of the entire abdomen with re-creation of a nice waistline, re-creation of highlights and shadows of the abdominal wall, elevation of the anterolateral thigh skin, and rejuvenation of the pubis. The incision is inside the bikini line. (*Below, left*) Preoperative lateral view. Observe the pouchy, weak abdominal wall with poor body posture. Also, observe the ptosis of the pubis and groin areas. (*Below, right*) Postoperative lateral view. Observe the significant improvement of the patient's abdomen. The rectus muscle looks tight. The excess skin on the anterolateral thigh has been elevated and the pubis rejuvenated.



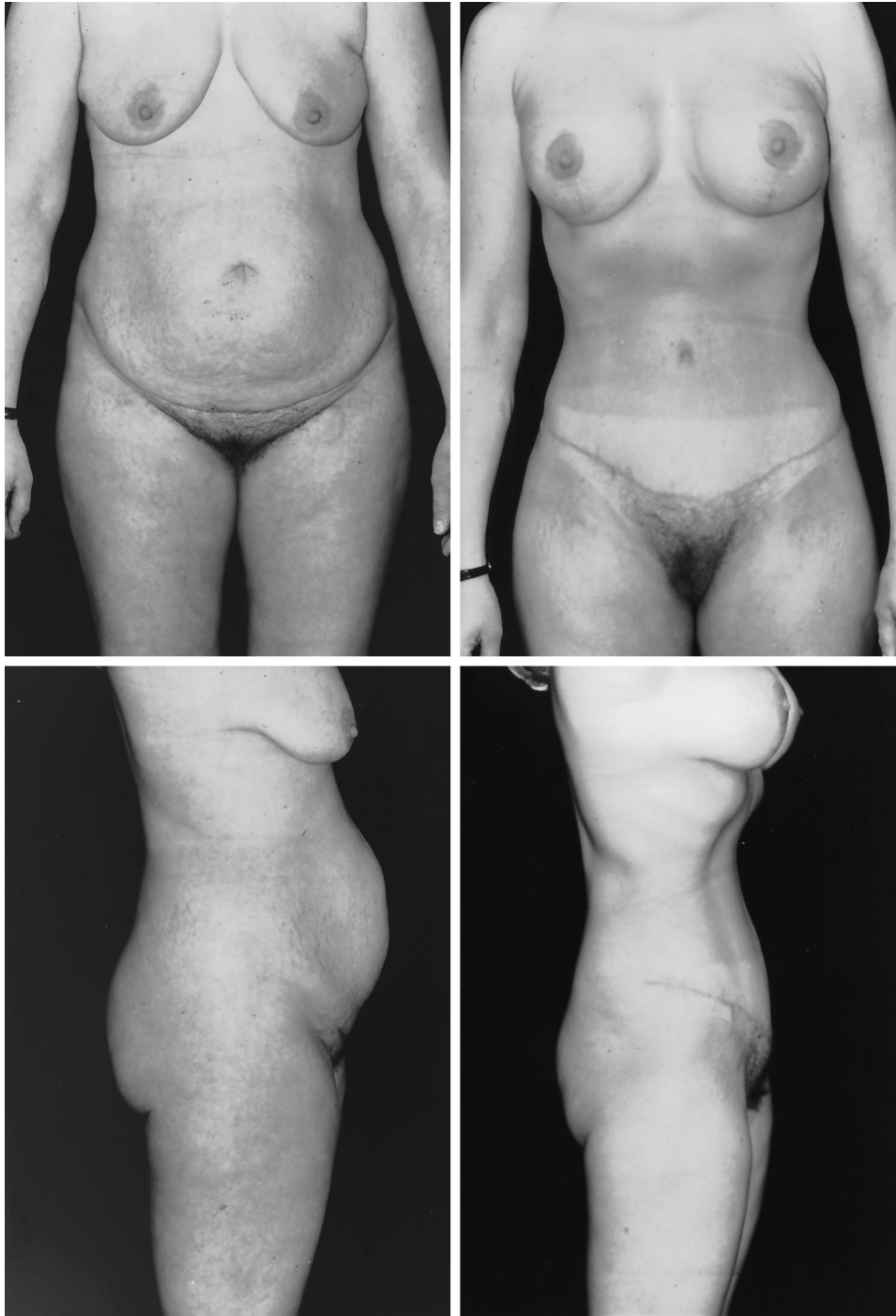


FIG. 9. (*Above, left*) Preoperative anteroposterior view of a 42-year-old woman who presented with significant abdominal wall laxity, poor body posture, and back pain. Observe the excess skin over the groin and the triangular pubis. (*Above, right*) Postoperative anteroposterior view. Observe the significant improvement of the patient's abdomen with decrease of the waistline and recreation of the aesthetic lines of the abdomen. Observe that the U-M incision has ended up inside the bikini line. Also, observe the lifting effect over the anterolateral thigh skin and pubis rejuvenation. The patient also had an augmentation/mastopexy procedure. (*Below, left*) Preoperative lateral view. Observe this patient's poor body posture with excessive lordosis. Observe the bulging abdominal wall. (*Below, right*) Postoperative lateral view. Notice the tight, athletic abdomen. There is a supraumbilical concavity. The lordosis has been corrected. The pubis and the groin skin have been lifted.

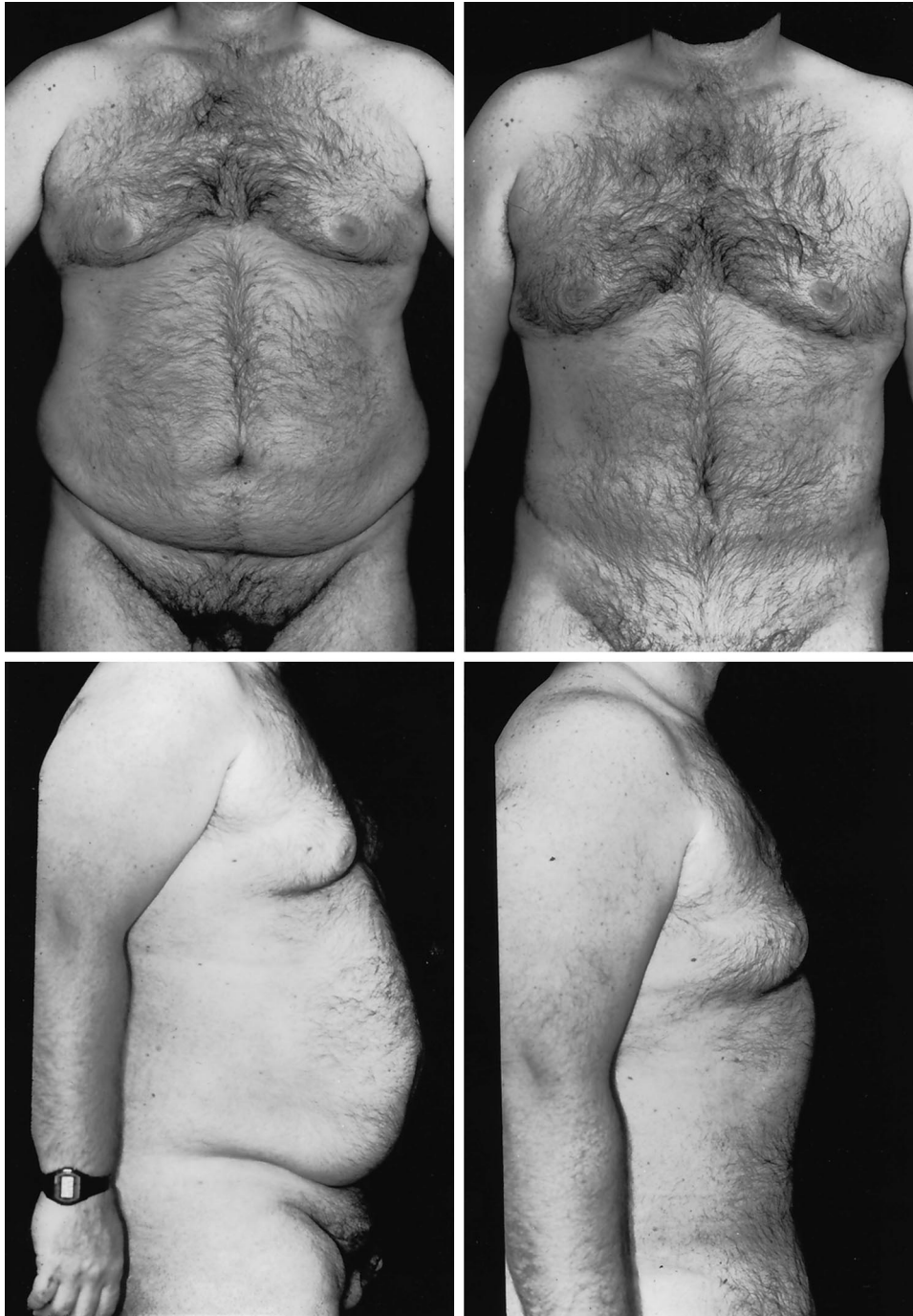

FIG. 10. (*Above, left*) Preoperative anteroposterior view of 40-year-old man with significant truncal obesity. The patient has a huge abdominal girth and excess abdominal panniculus. Also, observe the ptosis of the pubis and excess tissues over the groin. (*Above, right*) Postoperative anteroposterior view. Observe the reduction of the waistline, the elimination of the excess skin on the abdomen, and elevation of the pubis. The patient also had a concomitant suction lipectomy of the male breasts. (*Below, left*) Preoperative lateral view. Observe the huge abdominal panniculus, laxity of the abdomen, excess tissue on the groin, and ptosis of the pubis. (*Below, right*) Observe the tight abdominal wall musculature, elimination of excess skin, and lifting of the structures neighboring the lower abdomen.

may be one of the reasons for a low rate of seroma formation in this series, despite the routine use of suction lipectomy.

It may be argued that the more curvilinear incision of the U-M abdominoplasty may leave a flap with a relatively higher length/width

ratio and that the collateral blood flow to the distal flap may be diminished compared with a more horizontal incision. However, this theoretical happenstance has not occurred. The rate of skin necrosis has been less in this series than when using horizontal incisions, despite a more liberal use of concomitant suction lipectomy. This finding is probably because the tension of closure is more lateral than central. Although not proved, it is also feasible that the lateral portions of the flap may "steal" blood supply from the central portions in the more horizontal incisions.

Because of the significant redefinition of muscle tension in the abdomen, the symptoms of all of the patients with a history of back pain have improved. This relief is probably due to an indirect pull of the internal oblique-transversus abdominis muscles over the lumbo-dorsal fascia with reduction of stress at the intervertebral joint as postulated by Gracovetzky et al.<sup>12</sup> and clinically demonstrated by Toronto<sup>13</sup> and also observed by us.<sup>5</sup> The significant reduction of weight on the abdominal apron and the abdominal muscle tightening accounts for the improvement in body posture. This improvement has been observed in the majority of patients, and they have emphasized this fact too.

#### CONCLUSIONS

A comprehensive approach for the treatment of complex abdominal wall aesthetic defects is presented. Many of those patients also have associated functional defects. Correction of these problems requires multiple techniques. The procedures described here, i.e., U-M abdominoplasty, suction lipectomy, V umbilicoplasty, and the rectus myofascial release/repair, are integrated procedures. Each of the procedures helps maximize the positive influ-

ence of the other. These have allowed us to have predictable, reproducible, and aesthetically pleasing results. The rate of patient satisfaction has been extremely high.

Oscar M. Ramirez, M.D.  
Esthetique International  
2219 York Road, Suite 100  
Timonium, Md. 21093  
oscar@ramirezmd.com

#### REFERENCES

1. Ramirez, O. M. "U-M abdominoplasty." *Aesthetic Surg. J.* 19: 279, 1999.
2. Baroudi, R., and Ferreira, C. A. Contouring the hip and the abdomen. *Clin. Plast. Surg.* 23: 551, 1996.
3. Lockwood, T. High-lateral-tension abdominoplasty with superficial fascial system suspension. *Plast. Reconstr. Surg.* 96: 603, 1995.
4. Juri, J., Juri, G., and Raiden, G. Reconstruction of the umbilicus in abdominoplasty. *Plast. Reconstr. Surg.* 63: 580, 1979.
5. Ramirez, O. M., Ruas, E., and Dellon, A. L. "Component separation" method for closure of abdominal-wall defects: An anatomic and clinical study. *Plast. Reconstr. Surg.* 86: 519, 1990.
6. Nahas, F. X., Ishida, J., Gemperli, R., and Ferreira, M. C. Abdominal-wall closure after selective aponeurotic incision and undermining. *Ann. Plast. Surg.* 41: 606, 1998.
7. Matarasso, A. Liposuction as an adjunct to a full abdominoplasty. *Plast. Reconstr. Surg.* 95: 829, 1995.
8. Ramirez, O. M., and Galdino, G. Does tumescent infiltration have a deleterious effect on undermined skin flaps? *Plast. Reconstr. Surg.* 104: 2269, 1999.
9. Lewis, C. M. Early experience with aspirative lipoplasty of the abdomen. *Aesthetic Plast. Surg.* 11: 33, 1987.
10. Greninger, R. F. The mini-abdominoplasty. *Plast. Reconstr. Surg.* 79: 356, 1987.
11. Faria-Correa, M. A. Abdominoplasty: The South American Style. In O. M. Ramirez and R. K. Daniel (Eds.), *Endoscopic Plastic Surgery*. New York: Springer-Verlag, 1996.
12. Gracovetzky, S., Farfan, H., and Helleur, C. The abdominal mechanism. *Spine* 10: 317, 1985.
13. Toronto, I. R. Resolution of back pain with the wide abdominal rectus plication abdominoplasty. *Plast. Reconstr. Surg.* 81: 777, 1988.